

InFilling the Biologic Void™

Because traditional implant systems fall short

PINNACLE
SPINE GROUP

Insight. Innovate. InFill.™

www.pinnaclespinegroup.com

InFilling the Biologic Void *Why other fusion systems fall short*

by Zach Sowell, President, Pinnacle Spine Group

Eliminating the Performance Gap

Lumbar fusion has become a standard for spinal stabilization. Techniques and approaches have evolved, but all are predicated on well-established fusion principles: thorough disc preparation, proper endplate preparation, and placement of a critical mass of bone graft in contiguous contact with the vertebral endplates.

Challenge: Graft-to-Endplate Contact

Obtaining a robust fusion—particularly in the lumbar region—can present many challenges for surgeons. Managing bone graft delivery and maximizing its efficiency has long been cumbersome for surgeons as evidenced by the different techniques for using graft and various advances in biologic materials.

One critical challenge is caused by the disparate nature of the vertebral endplate geometry and the surface geometry of the implant. The space between the implant and the endplate is defined as the "biologic void". Delivering bone graft to the implant *in situ* optimizes graft contact with the endplates by maximizing the fill of the disc space, and eliminates waste and OR time while providing the highest opportunity for achieving a robust fusion.

Solution: InFilling the Biologic Void

Through research and clinical experience with the InFill technique, it is well understood that a larger area of contact between bone graft and well-prepared vertebral endplates improves the chances of a successful fusion.

The InFill approach—using a unique integrated system of instrumentation, implant designs and graft delivery system—the surgeon can safely inject bone graft into the implanted cage to fill the biologic void and promote optimized graft contact with the endplates. In addition, by more efficiently filling the biologic void—whether by InFilling an empty cage or by topping off a pre-packed cage *in situ*—many surgeons who use the InFill system require less OR time.

Biologic Void

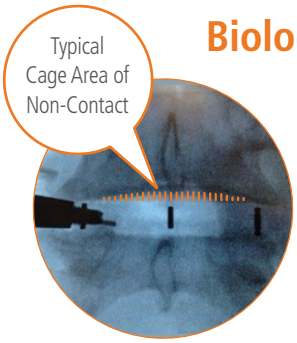

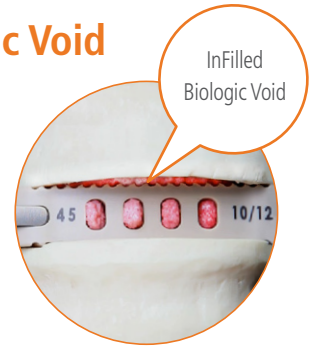

Up to 94% more **graft volume** | to promote greater endplate contact*

Traditional Pre-Packed
Note the biologic void, the region of non-contact

InFill® Advantage
Optimized graft-to-endplate contact to fill the bologic void

InFill Technique for Spinal Fusion Procedures

We believe that maximizing contact between graft and a well-prepared endplate is the best way to promote robust spinal fusion. With this in mind, Pinnacle Spine Group pioneered the unique InFill approach—the first intuitive spinal fusion system with integrated in situ *graft delivery capabilities. InFill is a versatile system designed to allow greater graft volume to fill the biologic void and promote optimal graft-to-endplate contact with best-in-class instrumentation, unique implant designs and multiple retractor options.*

info@pinnaclespinegroup.com
214 466 1428
www.pinnaclespinegroup.com/infill

InFill Interbody Fusion Systems

Designed for a more complete fill of the biologic void and greater graft-to-endplate contact.

Because ***Fusion Is A Contact Sport™***

PINNACLE SPINE GROUP

Insight. Innovate. InFill.™

* Burak M. Ozgur, MD FAANS, Erin Gleckman, PA-C (2013) InFill® Lateral System: a novel technique for optimizing graft filling and endplate contact in lumbar interbody fusion surgery.

Table of Contents

PINNACLE
SPINE GROUP

Insight. Innovate. InFill.™

Section 1: Introduction

InFill Interbody Fusion Systems

World's first intelligent, intuitive spinal fusion system with integrated *in situ* graft delivery capabilities

- Designed to allow maximum graft volume to help fill the biologic void and optimize contact with the vertebral endplate.
- Featuring a wide array of unique intervertebral implant designs and an innovative graft delivery system that set a new standard for controlled *in situ* graft delivery.
- Engineered to deliver optimal bone graft volume (up to 94% more) and precise graft placement to promote improved graft-to-endplate contact over traditionally pre-packed implants.
- Conceived with the goal of better fusion outcomes.

PINNACLE
SPINE GROUP

Insight. Innovate. InFill.™

InFill®
Interbody Fusion Systems

The only patented technology that allows maximum bone graft-to-endplate contact for posterior interbody lumbar fusion.

Eliminate The Performance Gap

Lumbar spinal fusion has become a standard for spinal stabilization. Various techniques and approaches have evolved, but all are predicated on well-established fusion principles. These principles include thorough disc preparation, proper endplate preparation, and placement of a critical mass of bone graft material in contiguous contact with the vertebral bodies.

Issue:

A universal challenge surgeons face during lateral fusion procedures is the lack of graft-to-endplate contact during cage placement. Endplates of the lumbar vertebrae are usually concave, while the contact points of the cage are typically flat. This results in a gap in surface area between the bone graft and endplate. This area of non-contact is called the "biologic void".

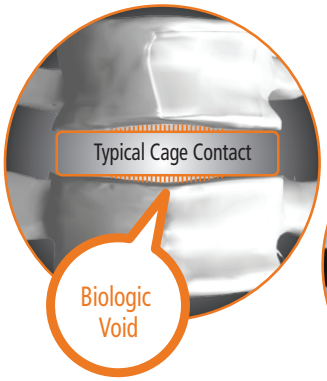

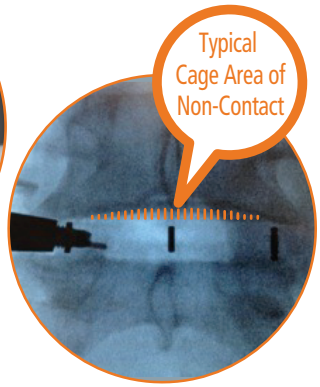

In order to overcome this gap, surgeons have traditionally relied on powerful and expensive biologic products to increase the chances for fusion to occur.

Solution:

The InFill system is designed to help solve this issue. Using patented InFill technology, the surgeon can safely inject supplemental bone graft material into the cage after implantation to fill the biologic void and achieve complete endplate-to-endplate contact with the bone graft.

INFILL® GRAFT DELIVERY TECHNOLOGY

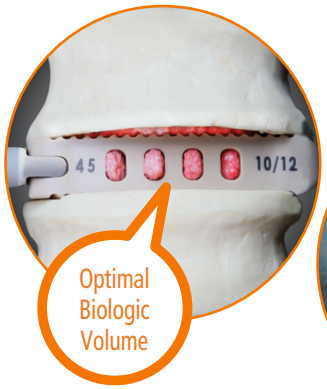

Due to the ability to fill the biologic void, many surgeons who use the InFill system require less expensive biologics to achieve a robust fusion. In many cases, the use of expensive BMP products in this procedure has been completely eliminated.

info@pinnaclespinegroup.com
214 466 1428
pinnaclespinegroup.com

Eliminate the performance gap with InFill Interbody Fusion Systems.
Because ***Fusion Is A Contact Sport***™

PINNACLE
SPINE GROUP

Insight. Innovate. InFill.™

PSG05232016

Section 2: Technique

InFill Graft Delivery System

Endplates of the lumbar vertebrae are usually concave, while the contact points surfaces of the fusion implant/cage/device are typically flat. This results in a gap in surface area between the bone graft and endplate – known as the biologic void.

Historically, surgeons have relied on expensive biologic products to increase the chance for a successful fusion, when better contact between bone graft and endplate is the true goal.

Using the patented InFill technology, surgeons can safely inject graft material into the cage after implantation to fill the biologic void and achieve a more complete endplate-to-endplate contact of the bone graft material.

Because of the more effective approach to filling the biologic void, many surgeons who use the InFill System require less expensive biologics to achieve a robust fusion.

Controlled, Contained and Directed Delivery

InFill® Graft Delivery System

- Syringe comes with spindle drive and standard plunger to drive easy transfer of graft material into cannula.
- Insertion tool or delivery guide tool directs cannula to access port on fusion device.
- Metal plunger offers tactile feedback for precise placement of graft material into and around fusion device.

InFill®

Interbody Fusion Systems

Graft Delivery, Engineered From Better Insight

Up to 94% MORE

Graft Volume

to promote greater **endplate contact**

Because Fusion Is A Contact Sport™

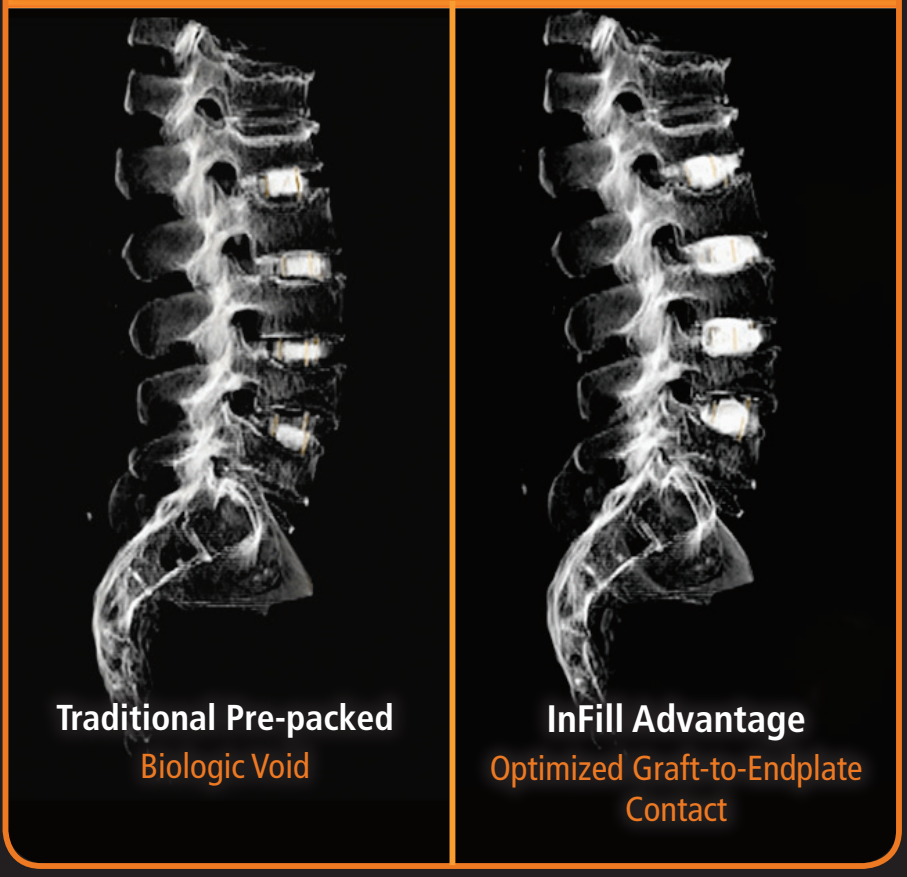

Research has shown that in many lumbar interbody fusion procedures, less than 50% of the disc area is actually grafted. One of the prime reasons for this is insufficient quantity of bone graft between the endplates.* This is why we pioneered *in situ* graft delivery with our patented InFill® interbody devices and graft delivery system. InFill delivers optimal graft volume and placement, and up to 94% more graft material between the vertebral endplates than traditional pre-packing alone, optimizing graft-to-endplate contact.**

* W Sukovich. Progress, Challenges And Opportunities In Disc Space Preparation For Lumbar Interbody Fusion. The Internet Journal of Spine Surgery. 2004 Volume 1 Number 2.

** Burak M. Ozgur, MD FAANS, Erin Gleckman, PA-C (2013) InFill® Lateral System: a novel technique for optimizing graft filling nd endplate contact in lumbar interbody fusion surgery.



InFill® Cannula Volume

	OD	ID	GRAFT VOLUME CC
Disc Fill Tube	8mm	6mm	4.25cc
Lateral Tube	4.8mm	4mm	4.0cc
TLIF Tube	3.5mm	2.5mm	1.0cc

1

Disc Fill

The InFill disc fill cannula can be used to fill a disc space prior to implanting the fusion device, allowing for implant encapsulation and more complete contact with the well prepared endplates.

2

Lateral

The InFill lateral cannula delivers bone graft material directly to the graft chamber and allows for material to flow out of the specially designed vents into the anterior disc space and ensure optimal graft-to-endplate conact.



3

TLIF

The smaller InFill TLIF cannula can be used to pre-fill the disc space, and then post-fill the TLIF implant. The proprietary anterior vent angle directs graft material for optimal placement in the disc space.

Intelligent, intuitive, patented

spinal fusion technology

with integrated *in situ* graft delivery

PINNACLE
SPINE GROUP

Insight. Innovate. InFill.™

Section 3: Case Study

InFill Technique

The results of this pilot study demonstrate successful increase in inter-body space and cage filling with greatly enhanced endplate surface contact by utilizing this novel inFill technique. Volumetric analyses by 3-D CT scanning demonstrates a range of 35-94% increase depending on lumbar spine levels as well as improved graft endplate surface contour filling and contact.

InFill®
Interbody Fusion Systems

InFill® Lateral System

A novel technique for optimizing graft filling and endplate contact in lumbar interbody fusion surgery

Burak M. Ozgur MD FAANS[a]

and

Erin Gleckman PA-C[b]

Newport Beach, CA

[a] Burak M. Ozgur MD FAANS. Founder/Director ONE Brain and Spine Center, Newport Beach, CA.

Chief of Neurosurgery Spine, Hoag Hospital, Newport Beach, CA.

[b] Erin Gleckman PA-C. Physician Assistant to Burak Ozgur MD. Newport Beach, CA.

PINNACLE
SPINE GROUP

www.pinnaclespinegroup.com

Insight. Innovate. InFill.™

Abstract

Background

Lumbar spinal fusion has become a standard for spinal stabilization. Various techniques and approaches have evolved but all are predicated on fusion principles. Some of these principles include proper carpentry, discectomy, graft filling/packing, and endplate contact and fusion surface area.

Purpose

The purpose of this study is to evaluate the efficacy of a novel graft filling technique for maximizing interbody space and cage filling with optimizing graft endplate surface contact.

Methods

This pilot study was performed utilizing a full human cadaveric lumbar spine from T12-S1 and performing standard lateral approach discectomy and endplate preparation at four lumbar disc levels from L1-L5. Subsequently, standard lateral lumbar cages were inserted at each level pre-packed with standard graft material. Thin-cut CT scans with 3-D reconstructions were performed to demonstrate the standard cage and graft implantation with particular attention to volumetric analysis and endplate surface contact. The InFill lateral system technology was then utilized at each level to inject additional graft material into the interbody spaces and cages. CT imaging was repeated to attain comparison data for pre and post fill changes. Independent/clinically practicing radiologist made official CT scan reading of findings.

Results

At L1-L2, the pre and post injection graft volumes measured 3.038 and 5.115 cc respectively, demonstrating a change of 2.077 cc or an increase by 68%. At L2-L3, the pre and post injection graft volumes measured 3.136 and 5.376 cc respectively, demonstrating a change of 2.24 cc or an increase by 71%. At L3-L4, the pre and post injection graft volumes measured 3.584 and 4.836 cc respectively, demonstrating a change of 1.252 cc or an increase by 35%. At L4-L5, the pre and post injection graft volumes measured 3.528 and 6.851 cc respectively, demonstrating a change of 3.323 cc or an increase by 94%.

Conclusion

The results of this pilot study demonstrate successful increase in interbody space and cage filling with greatly enhanced endplate surface contact by utilizing this novel InFill technique. Volumetric analysis by 3-D CT scanning demonstrates a range of 35-94% increase depending on lumbar spine levels as well as improved graft endplate surface contour filling and contact. Published literature emphasizes the point that optimized interbody cage placement and graft filling with endplate surface contact apposition are all important elements directly correlated with successful fusion. Further studies and long-term fusion analysis will be supplementary, however thus far this study suggests this technique may enhance lumbar interbody fusion surgeries and outcome.

Introduction

Lumbar spine fusion has become one of the tools in surgical treatment of low back pain for the past few decades. Fusion has proven successful in treating many conditions of the lumbar spine that may cause low back pain including degenerative disc disease, facet arthropathy, adult degenerative scoliosis, instability and spondylolisthesis[1,2]. Many different surgical approaches to lumbar spine fusion have been described including anterior, posterior and lateral approaches. Cappuccino A et al. report the biomechanical profile of each is determined by the extent of resection of local supportive structures, implant size and orientation, and the type of supplemental internal fixation used[3].

There has been much variation in lumbar interbody fusion rates depending on the study, approach, cage and instrumentation. Radiographic outcomes in the study by Malham et al. were consistent with previously-reported results which showed fusion rate ranges between 91% and 100% with XLIF approach[4]. In the systematic review of fusion rates that Lee et al. performed, various studies on ALIF and PLIF approaches were reviewed and fusion rates varied depending on additional instrumentation ranging anywhere from 77%-95%[5]. Kim MC et al. found the fusion rate of TLIF in their study at the 2 year follow-up to be 95.4% which they reported was comparable to findings in other studies[6]. The overall fusion rate of stand-alone ALIF using the SynFix-LR system with BMP-2 was 90.6 %[7]. Marchi et al. in their study of lateral interbody fusion found that fusion was observed in 86.6% of the levels treated[8].

In evaluating the efficacy of this novel graft filling technique, the InFill Lateral System demonstrates a successful increase in interbody space and cage filling with greatly enhanced endplate surface contact.

Researchers have found that stability and size of the cage plays a role in the success of spinal fusion[9]. Kim Y concluded in the study of bone and cage interface that it is likely that the larger the disc area or pedicle diameter, the more stable the interbody fusion of the spinal segments[10]. Wider cages have been found to create better surface area while reducing subsidence[11]. Polikeit et al. concluded that cages should be designed to offer a large volume for interface between the bone and bone graft[12].

Endplate preparation is also important and removal of the central bony endplate for bone grafts has been noted to improve graft incorporation and has been recommended because it does not affect the compressive strength and promotes graft incorporation[13]. Endplates of the lumbar vertebrae are usually concave while most of the implants and cages are flat leaving a gap in surface area between the cage with graft and endplate[14]. We propose that an injectable graft material into the cage after implantation would create better contact with the endplate and cover more surface area to promote fusion and ultimately lead to faster fusion and higher fusion rates in the lumbar spine. This may lead to lower rates of pseudoarthrosis and improved patient outcomes.

Methods

This pilot study was performed utilizing a full human cadaveric lumbar spine from T12-S1 and performing standard lateral approach discectomy and endplate preparation at four lumbar disc levels from L1-L5. Various standard surgical tools were used to obtain maximal soft tissue removal including disc material and cartilaginous endplate yet preserving the bony endplates. Figure 1 demonstrates the cadaveric preparation.

Subsequently, standard lateral lumbar cages were inserted at each level pre-packed with standard graft material. Cages were manufactured by Pinnacle Spine and were standard 8/10(H) x 21(W) x 45(L) mm lordotic PEEK cages spacers. The manufacturer's volume (within the cage) is measured to be 3.4 cc. A drawing in Figure 2 demonstrates the cage and graft space. The cage has anterior 'vent' holes designed to allow graft/bone growth anteriorly. Calculating the space of the anterior vent holes takes the graft volume size to be 3.67 cc. This does not take into account the additional graft/bone growth that can take place superiorly and

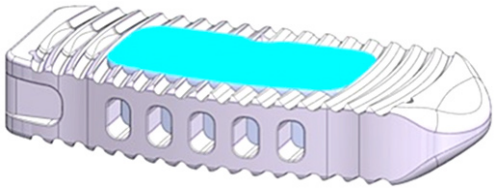

Figure 2: Drawing of the cage used and graft volume depicted.

Figure 1: Picture of cadaver preparation following standard lateral approach discectomy.

inferiorly towards the endplates. The graft material used was a Calcium Phosphate Biomaterial manufactured by Etex mixed with Omnipque for visualization purposes. 1.5cc of Omnipque was mixed with 10 cc of the saline-hydrated graft material. The same graft/omnipque mixture was 'injected' using the proprietary InFill technology after the initial imaging. It is of significant note that although cages were thoroughly packed prior to insertion, we observed that a significant amount of graft material falls out during insertion of the cage. This common phenomenon is demonstrated in Figure 3.

Thin-cut CT-scans (6 mm) with 3-D reconstructions were performed to demonstrate the standard cage and graft implantation with particular attention to volumetric analysis and endplate surface contact. The InFill lateral system technology was then utilized at each level to inject additional graft material into the interbody spaces and cages. CT imaging was repeated to attain comparison data for pre and post fill changes. Table 1 demonstrates the findings of the CT-scan report.

Figure 3: Picture of lateral cage and graft falling out during insertion.

Level	Pre InFill vol. (cc)	Post InFill vol. (cc)	Change in vol. (cc)	Increase
L1-L2	3.038	5.115	2.077	**68%**
L2-L3	3.136	5.376	2.240	**71%**
L3-L4	3.584	4.836	1.252	**35%**
L4-L5	3.528	6.851	3.323	**94%**

Table 1. Graft volumes and percentage change with InFill.

Results

The CT-scans were officially read out by a clinically practicing radiologist. These results are presented in Table 1. At L1-L2, the pre and post injection graft volumes measured 3.038 and 5.115 cc respectively, demonstrating a change of 2.077 cc or an increase by 68%. At L2-L3, the pre and post injection graft volumes measured 3.136 and 5.376 cc respectively, demonstrating a change of 2.24 cc or an increase by 71%. At L3-L4, the pre and post injection graft volumes measured 3.584 and 4.836 cc respectively, demonstrating a change of 1.252 cc or an increase by 35%. At L4-L5, the pre and post injection graft volumes measured 3.528 and 6.851 cc respectively, demonstrating a change of 3.323 cc or an increase by 94%.

Figures 4 and 5 demonstrate the sagittal 3-D images of the pre and post InFill injections of additional graft material respectively. Take particular notice of the dissipation of the gas/air space in the cage/endplate void in the pre Infill image (Figure 4). Also note the effective superior and inferior endplate opposition of graft as well as the proper depiction of concave endplate surface area contact demonstrated in the post InFill image (Figure 5).

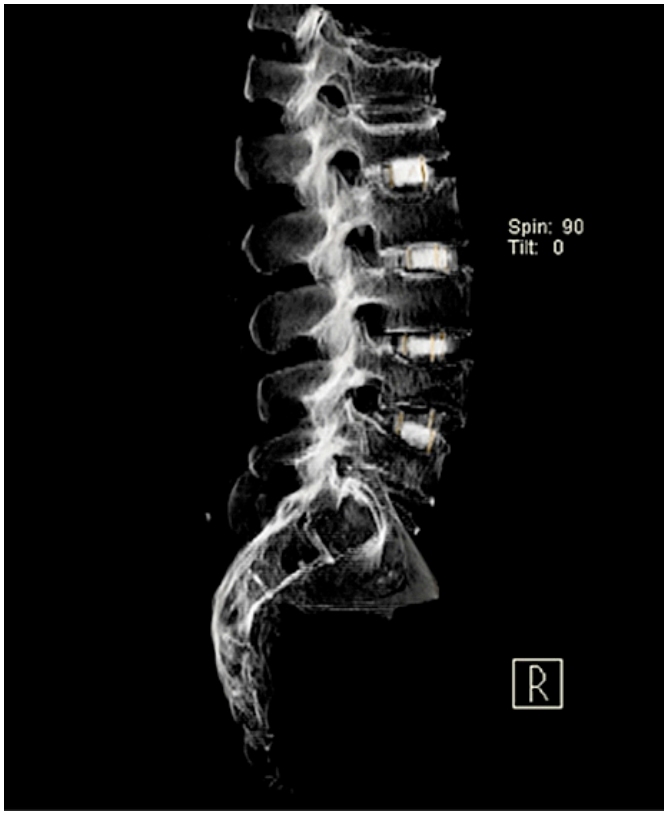

Figure 4: 3-D CT-scan image of pre Infill injection of graft material.

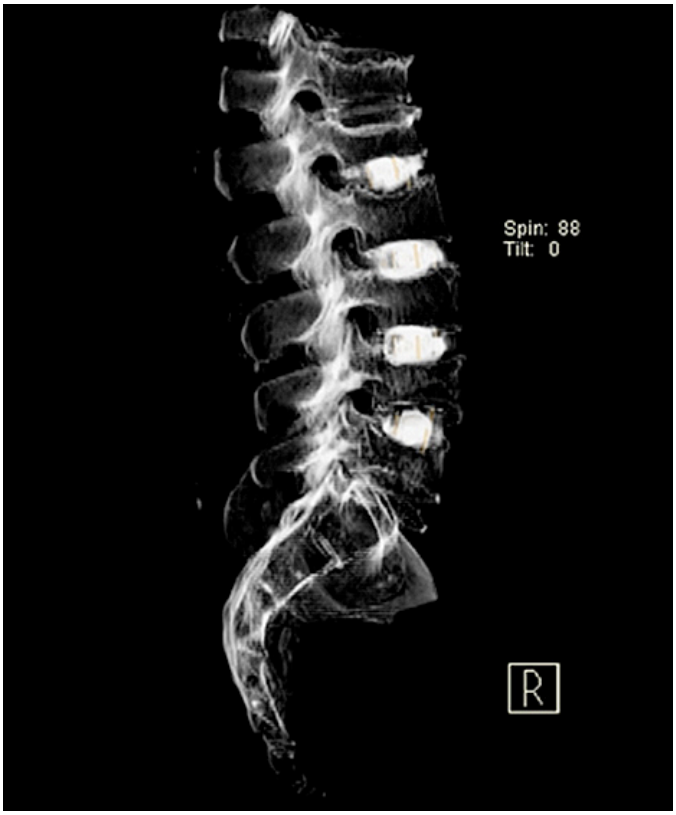

Figure 5: 3-D CT-scan image of post Infill injection of graft material.

Conclusion

Lumbar spinal stabilization and fusion has become a critical part of the armamentarium of the spine surgeon. We have always accepted the importance of classic and basic principles of complete discectomy, proper endplate preparation and cage packing. However, it has been increasingly important to analyze our outcomes in terms of successful fusions, rates of pseudoarthrosis, and costs in the changing healthcare-economic climate. The purpose of this study was to try and quantify the properties of cage packing, graft insertion, and potential benefits of additional graft packing post-insertion. The results of this pilot study demonstrate successful increase in interbody space and cage filling with greatly enhanced endplate surface contact by utilizing this novel InFill technique. Volumetric analysis by 3-D CT scanning demonstrates a range of 35-94% increase depending on lumbar spine levels as well as improved graft endplate surface contour filling and contact. Published literature emphasizes the point that optimized interbody cage placement and graft filling with endplate surface contact apposition are all important elements directly correlated with successful fusion. Jun BY quotes "successful arthrodesis in posterior lumbar interbody fusion requires both a large amount of graft and maximal graft filling"[15]. Additionally, Pumberger et al. emphasized that maximal structural graft or implant coverage of the endplates are of critical importance for fusion[16]. This pilot study demonstrates definitively that this InFill technology can aid in improving graft filling and attaining better space filling with endplate coverage and surface area contact. Additional work may demonstrate that this finding will then yield better fusion results and perhaps more efficiency in interbody space packing and cost effective use of graft materials, bone void fillers, and recombinant DNA technologies. Further studies and long-term fusion analysis will be supplementary, however thus far this study suggests this technique may enhance lumbar interbody fusion surgeries and outcome.

Volumetric analysis by 3-D CT scanning demonstrates a range of 39-94% increase in interbody space and cage filling with the InFill Lateral system, as well as improved graft endplate surface contour filing and contact.

Bibliography

1. Kaner T, Sasani M, Oktenoglu T, Ozer AF. Dynamic stabilization of the spine: a new classification system. *Turk Neurosurg*. 2010;20(2):205-215.

2. Panjabi MM. Clinical spinal instability and low back pain. *J Electromyogr Kinesiol*. 2003;13(4):371-379.

3. Cappuccino A, Cornwall GB, Turner AW, et al. Biomechanical analysis and review of lateral lumbar fusion constructs. *Spine (Phila Pa 1976)*. 2010;35 (26 Suppl):S361-367.

4. Malham GM, Ellis NJ, Parker RM, Seex KA. Clinical outcome and fusion rates after the first 30 extreme lateral interbody fusions. *ScientificWorldJournal*. 2012;2012:246989.

5. Lee CS, Hwang CJ, Lee DH, Kim YT, Lee HS. Fusion rates of instrumented lumbar spinal arthrodesis according to surgical approach: a systematic review of randomized trials. *Clin Orthop Surg.* 2011;3(1):39-47.

6. Kim MC, Chung HT, Kim DJ, Kim SH, Jeon SH. The clinical and radiological outcomes of minimally invasive transforaminal lumbar interbody single level fusion. *Asian Spine J.* 2011;5(2):111-116.

7. Behrbalk E, Uri O, Parks RM, Musson R, Soh RC, Boszczyk BM. Fusion and subsidence rate of stand alone anterior lumbar interbody fusion using PEEK cage with recombinant human bone morphogenetic protein-2. *Eur Spine J.* 2013.

8. Marchi L, Abdala N, Oliveira L, Amaral R, Coutinho E, Pimenta L. Stand-alone lateral interbody fusion for the treatment of low-grade degenerative spondylolisthesis. *ScientificWorldJournal*. 2012;2012:456346.

9. Le Huec JC, Liu M, Skalli W, Josse L. Lumbar lateral interbody cage with plate augmentation: in vitro biomechanical analysis. *Eur Spine J.* 2002;11(2):130-136.

10. Kim Y. Prediction of mechanical behaviors at interfaces between bone and two interbody cages of lumbar spine segments. *Spine (Phila Pa 1976)*. 2001;26(13):1437-1442.

11. Subach BR, Copay AG, Martin MM, Schuler TC. Anterior lumbar interbody implants: importance of the interdevice distance. *Adv Orthop.* 2011;2011:176497.

12. Polikeit A, Ferguson SJ, Nolte LP, Orr TE. The importance of the endplate for interbody cages in the lumbar spine. *Eur Spine J.* 2003;12(6):556-561.

13. Steffen T, Tsantrizos A, Aebi M. Effect of implant design and endplate preparation on the compressive strength of interbody fusion constructs. *Spine (Phila Pa 1976)*. 2000;25(9):1077-1084.

14. Lakshmanan P, Purushothaman B, Dvorak V, Schratt W, Thambiraj S, Boszczyk M. Sagittal endplate morphology of the lower lumbar spine. *Eur Spine J.* 2012;21 Suppl 2:S160-164.

15. Jun BY. Posterior lumbar interbody fusion with restoration of lamina and facet fusion. *Spine (Phila Pa 1976)*. 2000;25(8):917-922.

16. Pumberger M, Gogia J, Hughes AP, Kotwal SY, Girardi FP, Sama AA. Conventional manual discectomy versus powered discectomy for interbody fusion in the lumbar spine: cadaveric testing in forty levels. *J Spinal Disord Tech.* 2011;24(8):E71-74.

Section 4: Summary

InFill Advantage

Maximizing contact between graft and a well-prepared endplate may be the best way to promote robust fusion.

PINNACLE
SPINE GROUP

Insight. Innovate. InFill.™

Not using InFill® post-fill interbody fusion systems?
Here's what you're missing.

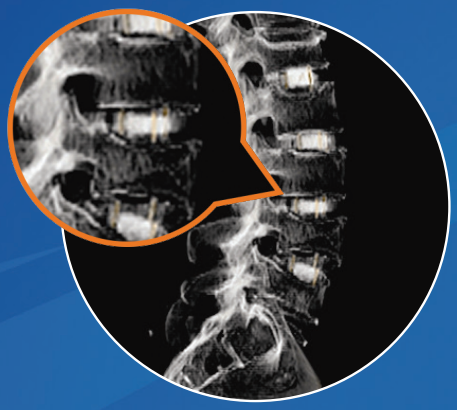

Traditional Pre-Packed
Biologic Void

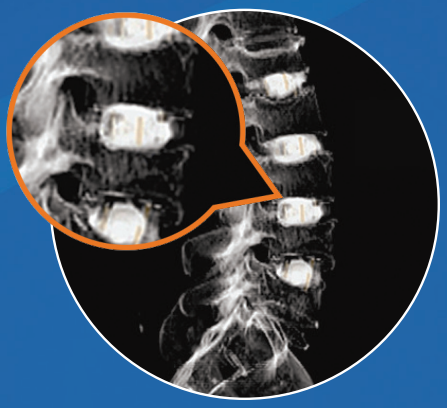

InFill® Advantage
Optimized Graft-to-Endplate Contact

Up to 94% more graft volume to promote greater endplate contact*

InFill®
Interbody Fusion Systems

Fusion Is A Contact Sport™

InFill Interbody Fusion Systems

Intelligent, intuitive, patented spinal fusion technology with integrated *in situ* graft delivery.

- *Engineered to deliver optimal bone graft volume, placement and graft-to-endplate contact*
- *Supports a complete post-fill, as well as a supplemental "topping off" of a pre-packed implant*
- *Featuring a broad array of unique implant designs and an innovative graft delivery system that sets a new standard for controlled* in situ *graft delivery*

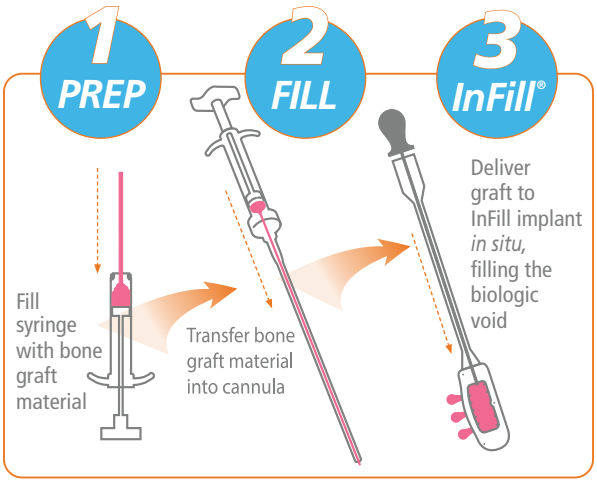

At Pinnacle Spine Group, we are committed to creating ground-breaking technologies for more effective spinal fusion outcomes. If you are too, we'd love to hear from you.

info@pinnaclespinegroup.com
214 466 1428
www.pinnaclespinegroup.com

PINNACLE
SPINE GROUP

Insight. Innovate. InFill.™

INFILL V2 LATERAL SYSTEM | INFILL ALIF | INFILL TLIF • *LORDOTIC • CONVEX • CONTOUR* | INFILL CERVICAL • *LORDOTIC • ANATOMIC*

* Burak M. Ozgur, MD FAANS, Erin Gleckman, PA-C (2013) InFill® Lateral System: a novel technique for optimizing graft filling and endplate contact in lumbar interbody fusion surgery.

Section 5: Contact

Eliminate The Perfomance Gap

At Pinnacle Spine Group, we believe a robust fusion column and maximized graft-to-endplate contact are critical for optimized fusion outcomes. We are committed to delivering innovative, ground-breaking technologies to achieve this goal, because we believe Fusion Is A Contact Sport™

To learn more, contact us today

Zach Sowell
President, Pinnacle Spine Group

info@pinnaclespinegroup.com

214 466 1428

www.pinnaclespinegroup.com

PINNACLE
SPINE GROUP

Insight. Innovate. InFill.™